

The Digital Restorative Model

The digital dental model increases the efficiency of restoration fabrication, is the only way to make a popular ceramic material, and gives the patient something to testify to his friends about his high-tech dentist.

by Todd Ehrlich, DDS

Abstract

The computerization of our society has definitely penetrated the dental industry and has an impact on material selection and efficiency. A popular dental material, zirconia, may only be made digitally. Although dentists continue to send physical impressions to their dental labs for these restorations, they must be digitized to allow for the CAD/CAM application of zirconia. With this process, a digital model is required.

If the doctor initiates the process with a digital optical scan, rather than a physical impression, the information can be analyzed by the doctor for preparation quality. This is done during the scanning process and prior to uploading the information through the Internet to their lab. Subsequently, the lab can use the digital model for restoration fabrication in a timely fashion. With modern tooth modeling algorithms and tools, the design process for the prosthesis is quickly rendered. Therefore, the restoration can be made efficiently and the patient can be delighted with the high-tech feel for the process.

Educational Objectives

1. Understand the basic digital optical scanning pros and cons.
2. Use digital scanning as a tool to analyze the quality of preparations.
3. Discover the various attributes and uses of a digital model.
4. Understand the opinion of laboratory owners with digital models and techniques.
5. Review current popular dental ceramics, like zirconia, and how they are made digitally.
6. Explore how computerized tooth modeling speeds up the restoration design process for the lab and dentist.
7. Recognize that digital dentistry has strong internal marketing implications for patients.

You can read the following CE article, take the post-test and Farran Media will submit the 1.5 continuing education credits. See instructions on page 127.

ADA C.E.R.P.® | Continuing Education Recognition Program

Farran Media is an ADA CERP Recognized provider. ADA CERP is a service of the American Dental Association to assist dental professionals in identifying quality providers of continuing dental education. ADA CERP does not approve or endorse individual courses or instructors, nor does it imply acceptance of credit hours by boards of dentistry.


Academy
of General Dentistry
PACE
Program Approval for
Continuing Education

Approved PACE Program Provider
FAGD/MAGD Credit
Approval does not imply acceptance
by a state or provincial board of
dentistry or AGD endorsement.
12/01/2004 to 12/31/2012

continued on page 122

As John waits in the chair to get his tooth “capped,” he flips through the news pages on Yahoo! with his new tablet. Although he really is not reading anything, he needs to look busy. He doesn’t want the dental assistant, and especially the dentist, to know he is nervous. Maybe not nervous so much, but anxious. How could he have been so stupid? He thinks back to the day when he accepted the job at the plant four years ago. The pay was not quite what he wanted, but the benefits were what finally sold him. However, for these last four years he neglected to use those benefits, and the toothache finally motivated him. Just a couple of weeks before, his new dentist said that he needed a root canal, gold crown and a bunch of fillings! How many did they say? He couldn’t remember. To top it off, the nice business lady at the front desk informed him that he had to get some things done quickly in order to “maximize” his dental insurance for this year which ended very soon. “If you don’t use it, you lose it!” she said. Although he didn’t understand the particulars, he trusted her thoroughness and direction. Why did I have to wait until my insurance was expiring? The newest smartphone he was eyeing will just have to wait until his next bonus. Besides, his tablet had all the latest features, and the new app his kids put on it was quite entertaining.

John’s sister-in-law, Susan, was notorious for exaggerating, but her graphic experience of a “cap” she had a few years ago was still troublesome: the impression, the temporary coming off, the adjustments! The thought of all that goop in his mouth concerned him the most because of his gag reflex. Every time he brushed his teeth he was reminded of it. And, he was supposed to brush his tongue, too? Impossible he always thought. There should be another way to make this crown.

Intra-oral optical impressions started in the 1980s with the evolution of CAD/CAM chairside milling of restorations.¹ The act of optical scanning involves a light-emitting camera that reads the light to varying depths of the three-dimensional surface. There are currently two types of scanners in the market today: imaging medium-free systems (ex., Cadent Itero, E4D), and imaging medium-dependent systems (ex., 3M Lava COS, Sirona CEREC). The scannable imaging medium material (also known as “powder”) uses titanium dioxide as its reflecting element. It can either be sprayed or painted onto the teeth.

Because the light of “powder-free” systems is absorbed and refracted by the tissue, there is less information reflected directly

to the camera for information. Therefore, systems that do not use an imaging material tend to need more images to detect and render the three-dimensional shape of the teeth being imaged. The optical scanning devices that require powder require fewer images because more light is directly reflected off of the material’s titanium dioxide and back into the camera. This gives more data per optical image.² There is a trade off with digital optical impressions: more pictures without imaging material, or fewer images while using imaging material.

Regardless of the method, intra-oral optical scanning has tremendous advantages for the clinician. At first use of the optical scanner, the clinician can instantly evaluate and discover the condition of the prepared teeth on the computer monitor (Fig. 1). While all dentists can visually evaluate their preparations, having the ability to see them as an instant digital model is priceless. Areas of the preparation that need attention, including inadequate reduction or rough margins, can be adjusted and improved prior to the master digital model being made (Fig. 2). In contrast with a physical impression, these faults cannot be seen while the impression is being made, and they might be missed altogether until the stone model is made from the impression. Therefore the preparations can be improved on immediately, and not at a subsequent patient visit (Fig. 3). Many clinicians might not see this as much of an advantage because their lab is able to routinely make their indirect restorations, but how often are our dental labs not telling us to improve our preparations? How often do they make things “work”? If a tooth preparation for an indirect restoration could be analyzed prior to master model completion, shouldn’t it?

The digital technique of direct information exchange from dentist to dental lab has been available since 2007. This link has expanded the possibilities of digitally processed restorations. Mohammad Al-Zu’bi, RDT of Genesis Dental Lab in Ontario reflects, “I was a skeptic at first, but I noticed that my digital doctors were delivering higher quality preparations because they could see irregularities before the information was sent. It is also very nice to have the digital models at my lab and at the doctor’s office.”

1. Mörmann WH. The evolution of the CEREC system. *J Am Dent Assoc.* 2006 Sep; 137. Suppl:7S-13S.
2. Stein JM. Stand-alone scanning systems simplify intraoral digital impressioning. *Compend Contin Educ Dent.* 2011 Nov-Dec;32 Spec No 4:56, 58-9.

Fig. 1

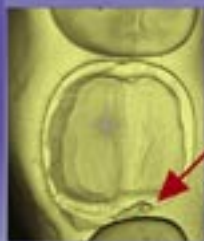

Fig. 2




Fig. 3




Fig. 1: Live viewing of the preparation allows one to see inadequacies immediately.

Fig. 2: Rough margin visualized instantly in digital model.

Fig. 3: Preparation is improved and new master model made.

continued on page 124

Digital models can be in two or more places at the same time as quoted by Mr. Al-Zu'bi. Therefore, the lab technician and the dentist can use them for better communication and multiple uses. Because of their digital nature, they never chip, degrade, wear out, and can be stored forever. They can also be manipulated digitally and enlarged on the monitor without a microscope. However, if a solid model is required, the digital model can be converted into a solid model. This is done by milling (ex., Cadent Itero) or digitally printing the model in resin (CEREC Inlab by Sirona.) (Fig. 4). Therefore, the digital model can be used for designing the restoration, and a fabricated model can be used for fit and finishing. For example, a gold crown can be made from a digital model a couple of ways:

1. A traditional wax-up of the crown shape can be made by a lab technician directly from a digitally fabricated model, rather than a stone model.
2. The gold crown can be designed digitally within a software, and the "wax pattern" can be milled, and cast.

The fit could also be confirmed on a digital hard model, but this is not necessary (Figs. 5 & 6). Bridges and multi-unit cases can also be designed off of a digital model and finished off the fabricated model from it. Therefore, if a bridge is being hand-stacked with ceramics, the framework is made digitally, and the stacked portion is completed off of the solid digital model (Figs. 7, 8 & 9).

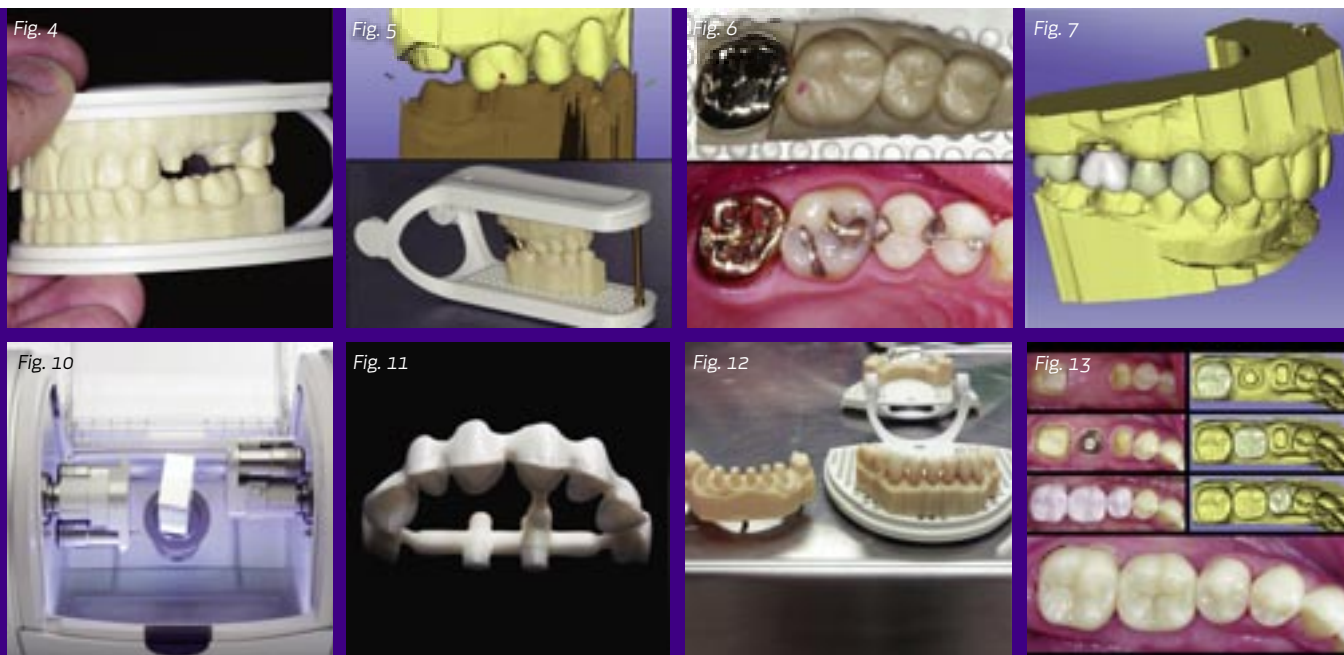All other dental materials can be made in a similar fashion if desired, but designing the restoration digitally than handmaking the shape is much more efficient. Frank Acosta, CDT at AA Dental Design in San Diego says, "The more digital models I work from the more I hate using stone models. The digitally based models I work from, whether in a computer or in my

hands, are much more efficient and reliable. I love the feedback that I get from my doctor clients about how well my restorations fit. They also appreciate the faster turn around time."

Dental ceramics continue to evolve, and one material that is extremely popular today is zirconia. Zirconia dental restorations are only made digitally using a CAD/CAM system.³ Therefore, there is a digital optical scan done at some point during the fabrication of every zirconia-based restoration. If a doctor takes a traditional physical impression for a zirconia crown, the dental lab must make a stone model from it. Then, the lab optically scans the stone model into the computer. The prosthesis can then be digitally designed, and milled. This process, however, negates the advantages of an intra-oral digital scan because everything is made from an analog stone model. If the original physical impression had any distortion, fins or variations, the restoration might not fit clinically. With a digital intra-oral scan the chances of inaccuracies are greatly reduced because the models are verified by the doctor and other factors like stone setting expansion are eliminated.

Zirconia-based restorations are primarily made by dental laboratories because of the complexity, large equipment required, and strict protocol for their manufacturing.³ These restorations are typically milled in what is referred to as the "green state." The green state is a state at which the material is only partially sintered and easier to mill with precise milling machines (Figs. 10 & 11). After milling, the material has to be sintered at very high temperatures (1,200 degrees Celsius+) for long periods of time. This is where the crystalline structure becomes the densest and

3. Vagkopoulou T, Koutayas SO, Koidis P, Strub JR. Zirconia in dentistry: Part 1. Discovering the nature of an upcoming bioceramic. *Eur J Esthet Dent.* 2009 Summer;4(2):130-51. Review.



achieves its desired physical properties. The pre-sintered green zirconia is made as a proportionally larger size (20-25 percent larger) than the desired shape. This is due to the crystalline structure becoming denser and therefore shrinkage occurs.³ The computer calculates this shrinkage percentage by the brand of zirconia being used and accommodates for it.

After the sintering process, the zirconia restoration is finished from a stone model or the digitally based milled or printed model (Fig. 12). The restoration can be made as full contour zirconia or layered with feldspathic ceramic or lithium disilicate. Regardless of how the material is finished, it could not be manufactured without a digital component to the process because the material is milled. Other ceramic materials are not limited to a digital component.

Feldspathic, leucite-reinforced, and lithium disilicate ceramics can be traditionally stacked, pressed and CAD/CAM milled. They also are considered the best when it comes to dental cosmetics. Therefore, these restorations have the widest range of use and are easier to make by the dental lab or even by the dentist. Because the digitized impression allows for very fast design of the restoration in computer software, it reduces the labor and therefore cost of the restorations. The feldspathic ceramics tend to be used less in the posterior because of a lower flexural strength of the material, and required bonding for cementation. The lithium disilicate materials have a higher strength than the feldspathic ceramics, and have excellent aesthetic properties. Because of this, they are extremely popular and advertised widely.

The popularity of lithium disilicate (ex., e.max Ivoclar Vivadent) among dentists has given dental labs more pressure to manufacture these restorations. Pressing this material using high pressure, heat and the lost wax technique is predictable but labor

intensive and time-consuming. Manufacturing the restorations digitally is easier with computer designing and milling a partially crystallized block of lithium metasilicate.⁴ The largest time consumption is a firing cycle, which is usually less than 25 minutes and in a standard ceramic oven with vacuum. However, this is greatly shorter than the sintering process of zirconia. Additionally, the material is much easier to work with after crystallization. A dental lab can reduce the turn around of the restoration even faster and predictably when the doctor uses a digital optical scan rather than a physical impression. Just like with zirconia, if a lab is to mill the restoration out of lithium disilicate, or feldspathic ceramic, an optical impression must be used. So, if the doctor initiates the procedure digitally from the beginning, the restoration can be sent over the Internet and made efficiently. If the doctor sends the lab a traditional physical impression, a stone model is made and then it is scanned into the computer by the lab.

Many times, the restorations do not even require a solid model. The efficiency of digital impressions, models and restorations has also allowed dentists to manufacture their own digital restorations using feldspathic, leucite-reinforced and lithium disilicate ceramics (Fig. 13). The computer-designing process of a restoration can be largely calculated, and at the end, needs very few adjustments. The “biogeneric” mathematical calculation (Sirona Dental Systems, CEREC) analyzes adjacent tooth morphologies and inter-maxillary space for its design. It goes through a database of naturally occurring teeth for which it finds the best anatomical shape to fit into the void of the prepared area (Fig. 14).^{5,6} The computer-calculated design process can also be utilized in the dental lab, which helps with efficiency. Litzenburger showed that a computer calculation was more precise than a laboratory wax-up of natural tooth morphology.⁷

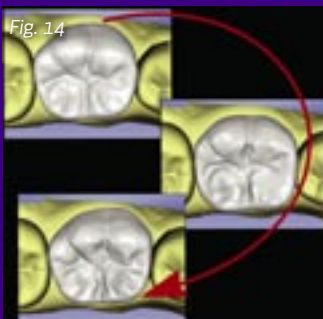
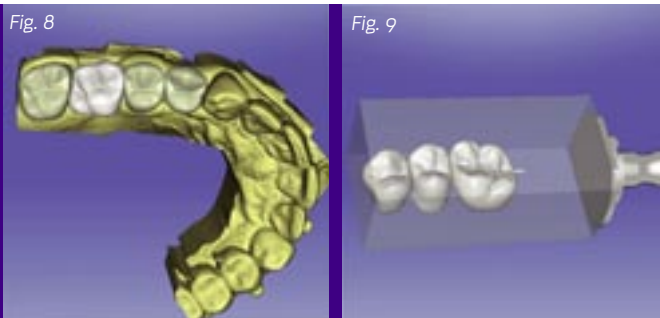


Fig. 4: Digital model converted to a hard model.

Fig. 5: Digital scan and corresponding hard model for gold crown.

Fig. 6: A digitally designed gold crown inserted.

Fig. 7: Multiple unit case articulated.

Fig. 8: Multiple units designed simultaneously.

Fig. 9: A digital bridge to be milled.

Fig. 10: Zirconia block about to be milled (courtesy of Mohammad Al-Zu'bi, RDT).

Fig. 11: Zirconia framework milled (courtesy of Mohammad Al-Zu'bi, RDT).

Fig. 12: Digital models ready for zirconia restorations (courtesy of Mohammad Al-Zu'bi, RDT).

Fig. 13: Digitally designed and milled lithium disilicate restorations.

Fig. 14: Multiple anatomical variations can be proposed.

4. Fasbinder DJ, Dennison JB, Heys D, Neiva G. A clinical evaluation of chairside lithium disilicate CAD/CAM crowns: a two-year report. *J Am Dent Assoc.* 2010 Jun;141 Suppl 2:10S-4S.
5. Mehl A, Blanz V. Biogeneric tooth reconstruction — new fundamental method to describe and reconstruct the occlusal morphology of teeth. In: Mormann WH, ed. *State of the Art CAD/CAM Restorations.* Hanover Park, Ill: Quintessence Publishing Co; 2006:113-121.
6. Ender A, Mörmann WH, Mehl A. Efficiency of a mathematical model in generating CAD/CAM-partial crowns with natural tooth morphology. *Clin Oral Investig.* 2011 Apr; 15(2):283-9. Epub 2010 Feb 9.
7. Litzenburger AP, Hickel R, Richter MJ, Mehl AC, Probst FA. *Clin Oral Investig.* 2012 Mar 27. Fully automatic CAD design of the occlusal morphology of partial crowns compared to dental technicians' design.

This is not to discount the ability of dental technicians but to show that a mathematical calculation will lead to a more precise shape faster. These computer programs that calculate these designs have excellent features that allow total customization of the design usually within minutes or seconds. The design features in modern CAD/CAM systems are highly sophisticated that allow multiple variations of anatomies, and allow the operator to fine tune any detail of the future restoration. Interproximal contacts can be designed to have customized size and intensity for which the clinical situation demands (Fig. 15). Customized occlusion pattern schemes can also be ordered by the dentist, or completed chairside (Fig. 16). Diagnosing and designing the occlusal scheme can be done in a very unique way that can only be done digitally.

A dentist may digitally scan the pre-operative condition of a tooth and utilize this three-dimensional information as a guide for the occlusal scheme. For instance, a tooth that has a large failing amalgam might require full cuspal coverage. The occlusal wear patterns present on the amalgam and the tooth can be used in the future digital design. This is done by overlaying, or correlating the pre-operative digital model exactly with the digital preparation model. The ghost image over the digital model shows exactly what has been taken away during preparation, and also a strong for the motion paths of the jaws (Figs.17 &18).

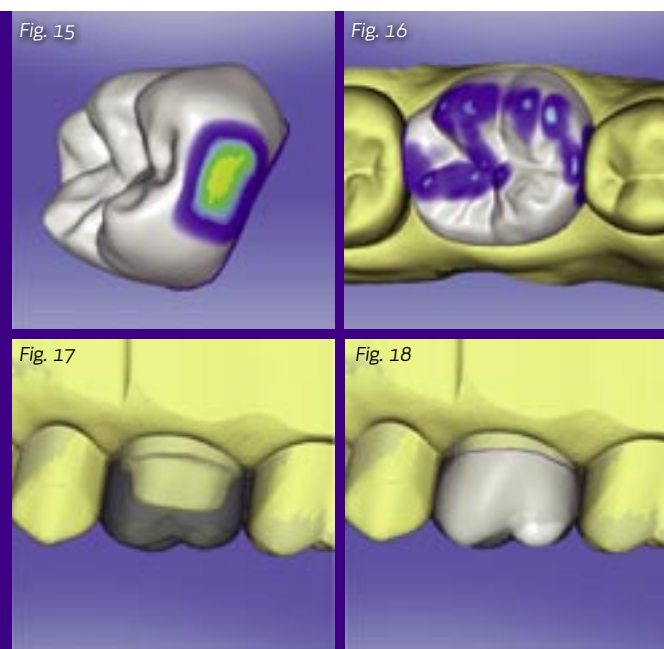


Fig. 15: Contacts are customized in strength and intensity.

Fig. 16: Occlusal pattern schemes are calculated by the computer.

Fig. 17: A ghost image of the pre-operative surface is a guide for the proposal.

Fig. 18: Areas where the digital proposal does not coincide with the pre-operative surface are seen in white.

Using this information, and a mathematically derived restoration design makes for an aesthetic restoration that meets the needs of the functional patterns of the patient.

The behind the scenes attributes of a digital model are never truly appreciated by the patient, but the visualization of an instant 3D model on a computer screen leads to a definite patient fascination. This heightens the patient's confidence with the doctor, and motivates him to refer friends for what he perceives as advanced dentistry. In addition, the turnaround time and predictable insertion of their restoration gives him opportunities to discuss his experiences with his friends and co-workers.

Complaints about dental treatment have always occurred, but what if some of the classic complaints were reduced: long turnaround times, goopy impressions, repeated adjustments, etc.? The digital model alleviates these complaints and gives talking points for our patients to compare treatment modalities. Why would a patient sing praises about how well a polyvinyl siloxane impression was done, or how they had to wait multiple weeks for a restoration? With digital optical impressioning and a digital model, he can have something to discuss and contrast with his friends who are making those complaints. Our patients are already digitized in so many ways: computers, high-definition televisions, smartphones, tablets, etc. How long will it be before they expect digital restorative dentistry much like everything else in their lives?

John turned off his tablet because his dentist was ready to begin. Unfortunately, he just couldn't get himself to tell him his concerns for gagging during the impression. "John, you can do this," he thought, and the chair started to lean back. The sounds, vibrations and occasional smell did not bother him. It was the anticipation of the impression that kept him from enjoying the Bruce Springsteen song flooding his ears. But, it never came, and the seat back started to rise with the snap of the doctor's gloves. John didn't understand, and his dentist began to show him how things are done digitally. The "impression" was done as a digital optical scan with a camera, and impression material was not necessary. The digital impression was being uploaded to his dental lab as they spoke. His gold crown would be ready in just a couple of days, and they would easily have it ready before his insurance expired. Fascinated by his experience, he would have to tell his co-workers, and definitely his sister-in-law, about this. ■

Author's Bio

Todd Ehrlich, DDS, is an advanced CAD/CAM trainer and beta tester for digital dental technologies. He is an administrator on Dentaltown's Web forums, and practices in Austin, Texas.



Post-test

Claim Your CE Credits

Answer the test in the Continuing Education Answer Sheet and submit it by mail or fax with a processing fee of \$36. We invite you to view all of our CE courses online by going to <http://www.dentaltown.com/onlinece> and clicking the View All Courses button. Please note: If you are not already registered on www.dentaltown.com, you will be prompted to do so. Registration is fast, easy and of course, free.

1. Three-dimensional dental optical impressions have been clinically done:
 - a. since the 1980s.
 - b. since the 1990s.
 - c. since the 2000s.
 - d. for the last three years.
2. Today's optical impressions:
 - a. use an imaging medium.
 - b. do not use an imaging medium.
 - c. are used as a preparation analysis tool.
 - d. All of the above
3. Software digital models can:
 - a. never chip or wear.
 - b. be manipulated.
 - c. be used at multiple locations.
 - d. be stored forever.
 - e. All of the above
4. Software digital models can be converted to hard models by:
 - a. milling them.
 - b. printing them.
 - c. pouring them in stone.
 - d. All of the above
 - e. a and b
5. Any desired dental material can be made from a digital model.
 - a. True
 - b. False
6. Zirconia-based dental restorations are made by:
 - a. the lost wax technique.
 - b. handstacking the zirconia.
 - c. CAD/CAM.
 - d. pressing under high heat and pressure.
7. Lithium disilicate-based restorations can be made by:
 - a. CAD/CAM.
 - b. handstacking.
 - c. pressing under high heat and pressure.
 - d. All of the above
8. Modern CAD/CAM software has tooth modeling features that:
 - a. compare adjacent teeth for anatomical shape.
 - b. use real-life dental anatomies as a guideline for shape.
 - c. are easily changed with tools.
 - d. All of the above
9. Prior to preparation, an optical impression and digital can be used as a reference for the final restoration occlusion and shape.
 - a. True.
 - b. False
10. Classic patient complaints that are alleviated with a digital scan and optical impression are:
 - a. no goopy material.
 - b. typically faster turn around time.
 - c. increased cost to the patient.
 - d. All of the above
 - e. a and b

Legal Disclaimer: The CE provider uses reasonable care in selecting and providing content that is accurate. The CE provider, however, does not independently verify the content or materials. The CE provider does not represent that the instructional materials are error-free or that the content or materials are comprehensive. Any opinions expressed in the materials are those of the author of the materials and not the CE provider. Completing one or more continuing education courses does not provide sufficient information to qualify participant as an expert in the field related to the course topic or in any specific technique or procedure. The instructional materials are intended to supplement, but are not a substitute for, the knowledge, expertise, skill and judgment of a trained healthcare professional. You may be contacted by the sponsor of this course.

Licensure: Continuing education credits issued for completion of online CE courses may not apply toward license renewal in all licensing jurisdictions. It is the responsibility of each registrant to verify the CE requirements of his/her licensing or regulatory agency.

continued on page 128

Continuing Education Answer Sheet

Instructions: To receive credit, complete the answer sheet and mail it, along with a check or credit card payment of \$36 to: Dentaltown.com, Inc., 9633 S. 48th Street, Suite 200, Phoenix, AZ 85044. You may also fax this form to 480-598-3450. You will need a minimum score of 70 percent to receive your credits. **Please print clearly. This course is available to be taken for credit July 1, 2012 through its expiration on July 1, 2015. Your certificate will be e-mailed to you within 3-4 weeks.**

The Digital Restorative Model by Todd Ehrlich, DDS

License Number _____

AGD# _____

Name _____

Address _____

City _____ State _____ ZIP _____

Daytime phone _____

E-mail (required for certificate) _____

☐ Check (payable to Dentaltown.com, Inc.)

☐ Credit Card (please complete the information below and sign; we accept Visa, MasterCard and American Express.)

Card Number _____

Expiration Date – Month / Year _____ / _____

Signature _____ Date _____

☐ Yes, I would like to continue receiving *Dentaltown Magazine* free of charge

(Signature required for subscription - free to U.S. only)

☐ No, thank you.

Program Evaluation (required)

Please evaluate this program by circling the corresponding numbers: (3 = Excellent to 1 = Poor)

- | | | | |
|---|---|---|---|
| 1. Course objectives were consistent with the course as advertised | 3 | 2 | 1 |
| 2. Course material was up-to-date, well-organized and presented in sufficient depth | 3 | 2 | 1 |
| 3. Instructor demonstrated a comprehensive knowledge of the subject | 3 | 2 | 1 |
| 4. Overall, I would rate this course | 3 | 2 | 1 |
| 5. Overall, I would rate this instructor | 3 | 2 | 1 |

For questions, contact Director of Continuing Education Howard Goldstein at hogo@dentaltown.com

CE Post-test

Please circle your answers.

1. a b c d
2. a b c d
3. a b c d e
4. a b c d e
5. a b
6. a b c d
7. a b c d
8. a b c d
9. a b
10. a b c d e

Field of practice (optional)

- | | |
|---|---|
| <input type="checkbox"/> General Dentist | <input type="checkbox"/> OMS Resident |
| <input type="checkbox"/> Anesthesiology | <input type="checkbox"/> Oral Pathology |
| <input type="checkbox"/> Consultant | <input type="checkbox"/> Orthodontics |
| <input type="checkbox"/> Cosmetic Dentistry | <input type="checkbox"/> Orthodontic Resident |
| <input type="checkbox"/> Dental Assistant | <input type="checkbox"/> Pediatric Dentistry |
| <input type="checkbox"/> Dental Company Rep. | <input type="checkbox"/> Pediatric Resident |
| <input type="checkbox"/> Dental Education | <input type="checkbox"/> Periodontics |
| <input type="checkbox"/> Dental Lab Tech | <input type="checkbox"/> Periodontic Resident |
| <input type="checkbox"/> Dental Student | <input type="checkbox"/> Prosthodontics |
| <input type="checkbox"/> Dental Hygiene Student | <input type="checkbox"/> Public Health |
| <input type="checkbox"/> Endodontics | <input type="checkbox"/> Radiology |
| <input type="checkbox"/> Endodontic Resident | <input type="checkbox"/> Speaker |
| <input type="checkbox"/> Front Office | <input type="checkbox"/> TMD Specialist |
| <input type="checkbox"/> Hygienist | <input type="checkbox"/> Other |
| <input type="checkbox"/> Implantology | |
| <input type="checkbox"/> Oral & Maxillofacial Surgeon | |