Fixed-Implant Rehabilitation

A contemporary approach

by Dr. Andonis Terezides

Dr. Andonis Terezides graduated from the University of Maryland School of Dentistry and completed his residency training in oral and maxillofacial surgery at Jackson Memorial Hospital/University of Miami.

Terezides, a diplomate of the American Board of Oral & Maxillofacial Surgery, enjoys practicing the broad scope of the specialty, with special emphasis in facial trauma and reconstructive surgery, tissue engineering, digital implant workflows, minimally invasive techniques, and full-arch and immediate-load implant rehabilitation. He is also a contributor to the Digital Dentistry Institute.

by Dr. Sundeep Rawal

Dr. Sundeep Rawal graduated from the University of Florida College of Dentistry in 2006. He completed his training in prosthodontics in 2009 at the University of California San Francisco, where he was exposed to the most current technologies shaping dentistry. Rawal worked extensively to utilize CAD/CAM technologies within the scope of clinical dentistry and enhance his patients' restorative treatments.

Rawal has lectured extensively across the U.S. and internationally, and has published papers in numerous dental journals. He is a co-founder of, and frequent contributor for, the Digital Dentistry Institute. He is in private practice in Orlando, Florida, and east to the Beaches.

Introduction

Despite monumental advances in modern dentistry and implantology, the number of fully edentulous patients and those with failing or nonrestorable terminal dentitions has not significantly decreased. This is in part because the dental field has been unable to keep up with the sheer volume of patients requiring full-mouth rehabilitation. Estimates from the World Health Organization and other research organizations indicate that there are more than 60 million fully edentulous people in the Western world and upward of more than 250 million fully edentulous people in Asia.

In the 1990s, Professor Per Ingvar Brånemark and a team of forward-thinking clinicians embarked on a scientific journey and mission to simplify treatment techniques to provide edentulous patients with a fixed full-arch implant rehabilitation. The initial studies involved the mandible. Paulo Malo and others began work on what was eventually known as the All-on-4 concept. As few as four implants could be used to support an immediate/interim fixed acrylic bridge implant prosthesis converted from a denture, which could be used for four to six months before proceeding on to a definitive fixed prosthesis.

At the same time, Brånemark and his colleagues introduced the Novum concept, using only three implants in the mandible that were placed by a standardized surgical template to support a prefabricated two-piece framework for a definitive screw-retained fixed prosthesis that could be delivered within 24 hours.

Both techniques had high success rates and patient satisfaction. These concepts paved the way for further improvement in implant design, surface treatment, prosthetic components, and eventual adaptation of the immediate implant/immediate provisionalization and loading of at least four implants in the maxilla.

Today, the All-on-4 treatment concept is considered a predictable and efficient treatment used daily to rehabilitate edentulous patients and those with a terminal dentition (Fig. 1).

There are, however, some anatomic challenges in the severely resorbed/atrophic maxilla that make the All-on-4 concept impossible without additional posterior implant anchorage. These have been successfully overcome in keeping with a graftless and immediate load approach

through the use of zygomatic implants. Additionally, an alternative and lower-cost treatment option in the mandible has been redeveloped to offer a fixed mandibular implant rehabilitation to a wider patient population.

In this article we will review the anatomic challenges and highlight our approach to these challenging situations through the use of zygomatic implants as a primary treatment method for the severely resorbed and atrophic maxilla and introduce a cost-effective therapy using Nobel Trefoil for a fixed mandibular rehabilitation.

Anatomic changes and challenges associated with edentulism

The loss of teeth in the maxilla leads to a progressive resorption of the residual alveolar ridge. This pattern of bone loss proceeds in a superior/posterior and medial/palatal direction (Figs. 2 and 3). This leads to changes in the facial morphology, giving a sunken-in, collapsed and aged appearance to the face without appropriate lip support. The resorption pattern may lead to a shallow or flattened palatal vault and lack of adequate vestibular depth. Additionally, over time patients often develop significant hyperpneumatization of the maxillary sinuses that extends anteriorly to the premaxilla.

In the mandible, the edentulous residual alveolar ridge resorption pattern proceeds inferiorly and laterally. Severe resorption cases can lead to exposure of the inferior alveolar nerve and mental neurovascular bundle to the top of the alveolar crest. With only thin mucosa overlying the exposed neurovascular bundle, the already difficult task of wearing and using a removable denture becomes painful and nearly impossible.

Fig. 1: *Maxillary and mandibular rehabilitation with the All-on-4 treatment concept.*

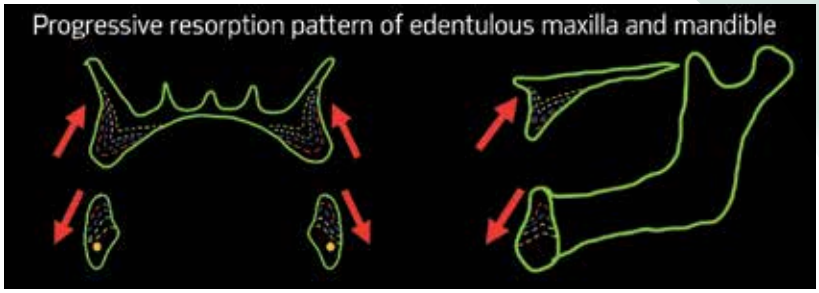

Fig. 2: *Resorption patterns of dental alveolar bone down to basal bone. (Left: coronal view. Right: sagittal view.)*

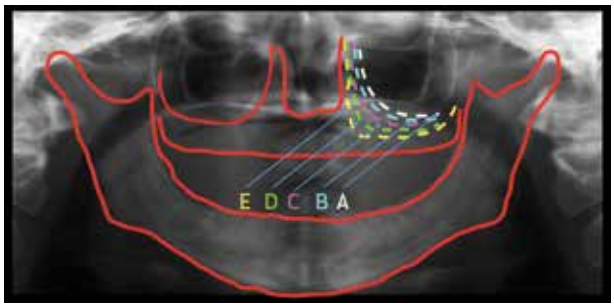

Fig. 3: *Brånemark classification of anterior maxillary sinus wall extension.*

This resorption pattern in both jaws results in an unfavorable Class III skeletal relationship as well as a crossbite relationship that creates significant surgical and restorative challenges in the patient's oral rehabilitation. In the most severe cases, the resorption proceeds all the way to the basal bone.

When evaluating a patient with a terminal maxillary dentition or one who is already edentulous, radiographic screening begins with a panoramic image. Potential available bone sites are identified using the Bedrossian zones (Fig. 4, p. 56). Careful clinical evaluation of the patient is performed to determine if there is a missing tooth-only defect or a composite defect. This evaluation includes determining the appropriate incisal edge position, need for lip support and the appropriate vertical

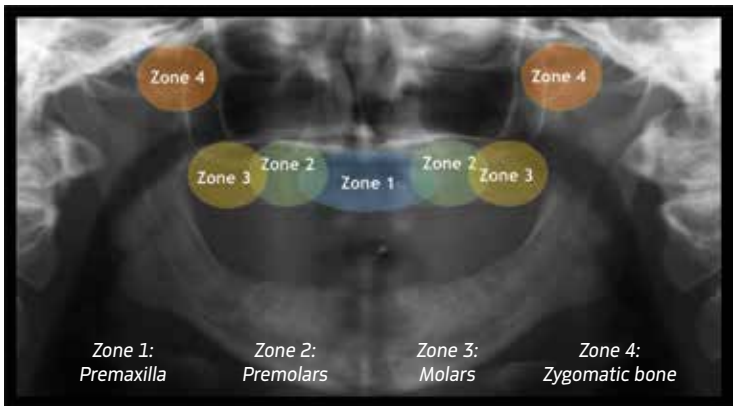

Fig. 4: *Bedrossian zone classification*

Bone Availability	Surgical Approach
Zones 1, 2, 3 (Lack of composite defect)	4–8 axial/traditional implants
Zones 1, 2 (Composite defect)	All-on-4 concept (4–6 implants)
Zones 1, 4 (Composite defect)	Anterior maxilla: 2–4 implants Posterior maxilla: 2 zygomatic implants
Zone 4 (Composite defect)	Quad zygomatic implants

Fig. 5: *Maxillary treatment algorithm for graftless or immediate load approach based on available bone, using the Bedrossian zone classification.*

Fig. 6: *Ad modum Brånemark technique, which sometimes necessitated a palatal emergence of the restorative platform*

dimension of occlusion. The need for bone-reduction or alveolectomy is also predetermined to provide for the necessary prosthetic component space, hiding the transition-zone and creation of a hygienic and cleansable prosthesis (Fig. 5).

Zygomatic implant therapy

Brånemark developed zygomatic implants in the mid-1980s for treatment of maxillofacial oncologic patients who had undergone maxillectomy procedures.

Later, zygomatic implants found use as alternative or last-resort options in full-arch maxillary rehabilitations—first in delayed or staged manner, and later as an immediate function/load approach to salvage cases while avoiding extensive bone-grafting procedures. Today, zygomatic implants are no longer considered alternative or last-resort options, but rather a routine, reliable and predictable primary treatment by many surgeons and prosthodontists.

The original Brånemark protocol dictated that the zygomatic implant would have quad-cortical stabilization based on a trajectory that proceeded from the palatal side of the residual alveolar process through the maxillary sinus, with subsequent entry into the zygomatic bone, ultimately exiting through the superior/lateral cortex of the zygoma. The main drawback from this approach was often a significant palatal emergence of the implant restorative platform, which then resulted in bulky prostheses, made hygiene more difficult and sometimes created difficulty with speech (Fig. 6).

Modifications of the ad modum Brånemark technique were developed by several clinicians such as Drs. John Stella, Carlos Aparicio and Paulo Malo in an effort to overcome some of the challenges, limitations and complications faced by using the original protocols.

Aparicio devised a classification system called the zygoma anatomy-guided approach, or ZAGA concept, which focused on an individual's anatomy rather

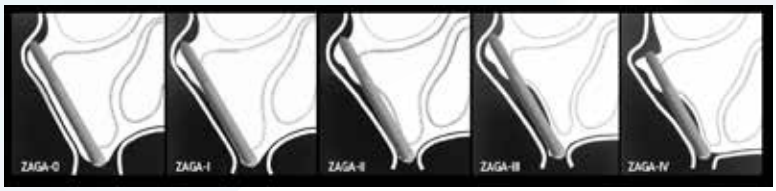

Fig. 7: *The zygoma anatomy-guided approach classification system depicts zygomatic implant trajectory based on the desired implant platform location and the lateral maxillary wall and sinus anatomy.*

Fig. 8: *Ideal prosthetic emergence of the zygomatic implant fixtures, achieved by treatment planning and placing the implants in accordance with the ZAGA classification.*

Fig. 9: *NobelZygoma 45-degree implant.*

than a standardized implant trajectory to determine the most ideal prosthetic position of the implant platform emergence. Using the ZAGA concept, Aparicio demonstrated that zygomatic implant surgery has the potential to be less invasive and faster, with less risk of sinus-related complications. It also provides improved prosthetic design/biomechanics, easier hygiene, and improved comfort, speech and aesthetics (Figs. 7 and 8).

Improvement in implant design and prosthetic options

After more than 20 years of experience and success using the original Brånemark machined and Ti-Unite surface-coated zygomatic implants, a redesign with improvement to the implants addressed some of the issues and complications such as mucosal dehiscence, sinusitis, prosthetic compromises and implant fracture. Most notably, the implants are fully treated with a Ti-Unite surface and the threads have been removed from the implant head and body to decrease mucosal irritation and risks of mucosal dehiscence. The implant apex has been modeled to resemble the NobelSpeedy implant, which was designed for bicortical anchorage and high initial primary stability.

The new design permits for improved bone-implant contact and improved soft-tissue attachment to the implant. The implant body has also been widened to provide for increased mechanical resistance and implant strength. The restorative interface of the implants is now also available in the traditional 45-degree platform and a flat zero-degree platform (Fig. 9).

All-on-4 treatment concept with zygomatic implants

A 77-year-old female presented with a failing maxillary PFM bridge and desiring a timely, less-invasive fixed-implant solution (Figs. 10–12, p. 58).

Figs. 10a–c: Maxillary terminal dentition. (a) Failing PFM bridge with nonrestorable recurrent decay; (b) bone present in Bedrossian zones 1 and 4; (c) treatment planning using NobelClinician software.

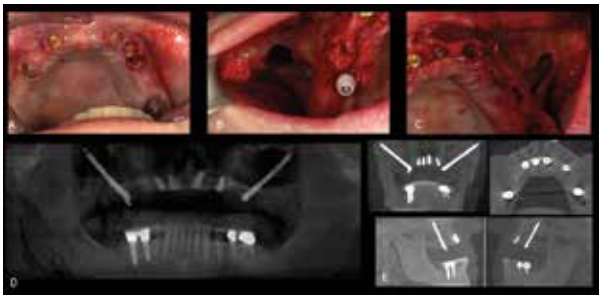

Figs. 11a–d: *Extractions, zygomatic implants and Nobel Active implants with immediate postop imaging. (a) Removal of failed bridge to reveal decayed retained roots; (b) right zygomatic implant 47.5mm (ZAGA 1); (c) anterior maxillary implants and left zygomatic implant 50mm (ZAGA 0); (d) immediate postop imaging demonstrating four Nobel Active implants in the anterior maxilla and two bilateral zygomatic implants.*

Figs. 12a–e: *Immediate-load fixed provisional restoration removed for final impressions at six months. (a) Note excellent A-P spread and healthy mucosal tissues; (b) implant provisional showing screw access holes; (c) retracted frontal view with multiunit abutments; (d) provisional prosthesis in place; (e) happy patient.*



Fig. 13: *Brånemark Novum, with its rigid double-bar framework, compared with the Nobel Trefoil, which has five self-adjusting joints designed to correct the bar position to ensure a passive fit of the prosthesis.*

A new mandibular solution

The Nobel Trefoil system (Fig. 13) is an innovation in mandibular full-arch rehabilitation. This concept has its scientific underpinnings in the original Brånemark Novum system popularized in the late 1990s and early 2000s. By using prefabricated surgical templates, three implants were placed in the anterior mandible and loaded with the definitive fixed prosthesis on the same day. Patients were pleased with the results and significantly decreased treatment time.

The implants showed excellent marginal bone stability and high survival rate, but there were some problems with the prosthetics because the prefabricated framework was so rigid and unable to compensate for some discrepancies in implant placement that a passive fit of the framework could not always be achieved, leading to prosthetic complications. Ultimately, the Brånemark Novum was abandoned in 2007 in favor of the All-on-4 treatment concept.

Dr. Kenji Higuchi believed that if techniques and materials could be developed to overcome the poor fit problems that led to prosthetic complications in the Novum system, a more affordable and less time-consuming approach to full-arch implant treatment could be realized for the mandible.

Higuchi believed that solution could allow patients to have a more affordable fixed mandibular implant prosthesis rather than having to opt for an implant-retained removable overdenture (Figs. 14 and 15, p. 60). Thus, after several years of research and re-engineering, the Nobel Trefoil system was developed to fit this patient niche. In 2015, the system began a prospective

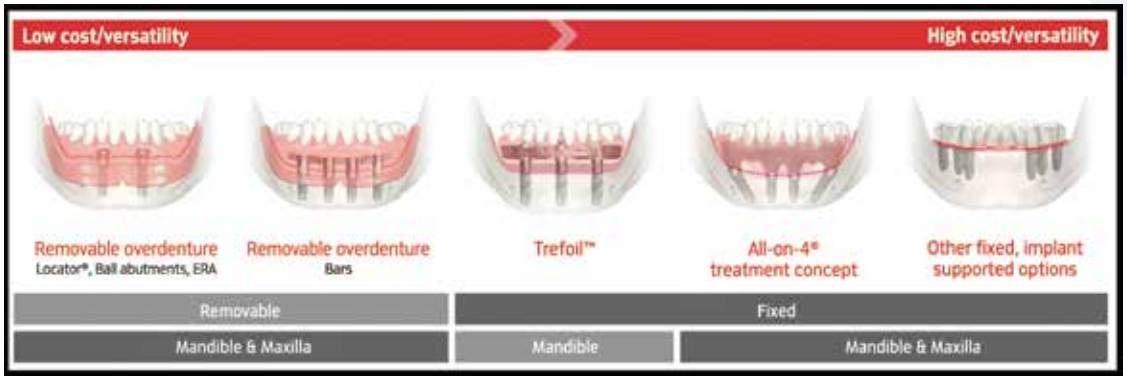

Fig. 14: *Nobel Trefoil is intended to serve as a lower-cost alternative for a fixed mandibular prosthesis.*

Fig. 15: *Nobel Trefoil bar demonstrating the adaptive compensation mechanism to ensure passive fit of the framework by compensating for angular, horizontal and vertical discrepancy in placement at each of the three implant fixtures.*

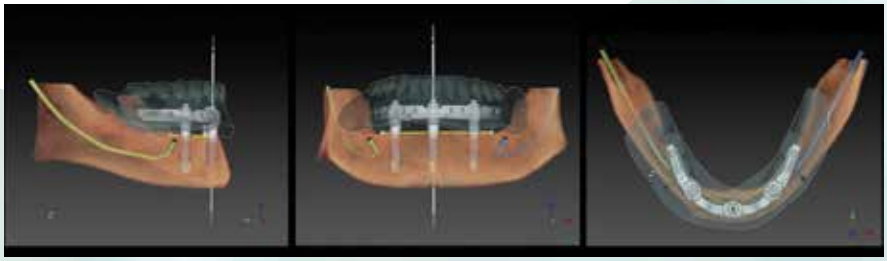

Fig. 16: *Preoperative planning Nobel Trefoil using NobelClinician software.*

multicenter, five-year study in the United States, Spain, Italy, Chile and Australia. The preliminary results have shown a 97.6 percent success rate regarding implant survival and a 98.2 percent success rate regarding prosthesis survival.

Aside from the novel compensation mechanisms to ensure a passive fit of the standardized prefabricated titanium framework, Trefoil offers several other unique features and advantages. The system offers guided surgery to place three implants in the anterior mandible, no required provisional prosthesis, significantly reduced chair time with simplified restorative procedures, simplified laboratory protocols, and delivery of the definitive prosthesis the same day or within 24 hours.

It should be noted that Trefoil was not designed or intended to replace any currently accepted implant treatment method for the mandible. Rather, it is meant to serve as another solution in the surgical and prosthodontic armamentarium to provide patients an efficient, cost-effective,

Figs. 17a–g: *Nobel Trefoil procedure. (a) Bone leveling/reduction; (b) guide pin demonstrating 22mm of prosthetic space; (c) guided surgery; (d) implant sites with V-template in place; (e) three Nobel Trefoil implants, 11.5mm length with 4.5mm collar; (f) verification index with transfer abutments; (g) healing abutments in place and tissues sutured.*

Figs 18a-d: *Fabrication and delivery of the definitive Nobel Trefoil prosthesis within 24 hours of surgery. (a) Occlusal view; (b) frontal view; (c) intaglio surface; (d) definitive prosthesis delivered on first postoperative day after overnight lab processing.*

aesthetic, durable and predictable fixed-implant rehabilitation of the mandible.

Nobel Trefoil case example

A 55-year-old male with a failing mandibular dentition desired a fixed-implant solution (Figs. 16–18).

Conclusion

Brånemark had a vision of simplifying treatment for patients: "A decisive factor in patient care is simplification of dental treatment, which should be based on identifying and utilizing the enormous capacity of existing original anchoring tissues. When possible, one should avoid unnecessary, advanced and complicated major grafting procedures."

Supported by a vast array of long-term scientific literature, our treatment philosophy follows Brånemark's vision by successfully caring for the edentulous and terminal dentition patient population through the use of digital diagnostics and treatment-planning technology, minimally invasive, graftless surgical procedures, immediate-load/provisionalized fixed-implant prosthetic solutions and personalized patient care. ■