THE LONGEST CASE HISTORY

Reported in Dental Literature?



1946
2016

A 70-year follow-up of vital pulpotomy using calcium hydroxide paste

The patient, age 82, with authors Fredrick M. Berk and Dr. Ali Maddahi in February 2016.

By Ali Maddahi, MS, DMD
Fredrick M. Berk
Cornelis H. Pameijer, DMD, DSc, PhD

Ali Maddahi, MS, DMD, is in private practice in Framingham, Massachussetts, and serves on the part-time faculty of the Harvard School of Dental Medicine, Department of Oral Health Policy and Epidemiology. Maddahi also is on the clinical staff of Cambridge Health Alliance Windsor Dental Clinic.

Fredrick M. Berk is vice president of Pulpdent.



Cornelis H. Pameijer, DMD, DSc, PhD, is professor emeritus at the University of Connecticut, Health Center.

Vital pulpotomy aims to amputate the coronal pulp tissue of a tooth and maintain the vitality of the pulp, while a dressing placed on the radicular pulp tissue stimulates dentin bridge formation, protecting the pulp from possible subsequent irritation. There are many instances when the prognosis for direct pulp capping is doubtful but the prognosis for maintaining the vitality of the radicular pulp is good; in these cases, vital pulpotomy is a practical option that can be performed in one visit.[1]

Maintaining the vitality of teeth is important for function, aesthetics, proprioceptive responses, biological integrity, and development and/or maintenance of the alveolar bone of both maxillary and mandibular arches.[1] While indicated for both primary and permanent teeth, vital pulpotomy is especially important when treating children to maintain the integrity of the dental arch and promote its normal growth and development, and to allow immature teeth with wide-open apices and incompletely formed roots to fully mature. When the diagnosis is favorable for a vital pulpotomy, the procedure can be performed and the restoration completed in one visit, with considerable time and cost savings to the patient.

A calcium hydroxide aqueous methyl-cellulose paste has proven to be a successful pulpal dressing for vital pulpotomy.[1,7,10] Dental researchers have experimented with calcium hydroxide for nearly a century, starting with the German researcher Hermann.[2] Teuscher and Zander, and Zander et al.[3,4,5,6] reported that calcium hydroxide, when placed in contact with the pulp, stimulates healing with the formation of odontoblasts and new dentin. Berk reported that a calcium hydroxide aqueous methyl-cellulose paste produces consistently favorable results as a pulpal dressing for vital pulpotomy.[7] Stanley reported in 1989 on the long-term success of calcium hydroxide-methylcellulose in vital pulp therapy.[8] The method of action is attributed to the high pH and the ionic dissociation of $Ca(2^{+})$ and $OH(^{-})$ ions and their effect on vital tissue at the cellular level to induce responses.[9] Bai et al.[10] successfully performed vital calcium hydroxide pulpotomy on 25 young permanent incisors and reported formation of dentin bridges in all cases using Multi-Cal paste (Pulpdent).

***Fig. 1**: Histological section shows a localized pulpal abscess within the coronal pulp tissue. Prognosis for vital pulpotomy may be favorable.*

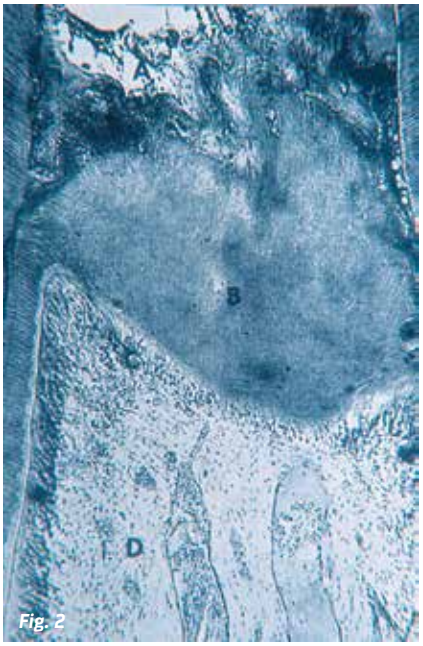

Fig. 2

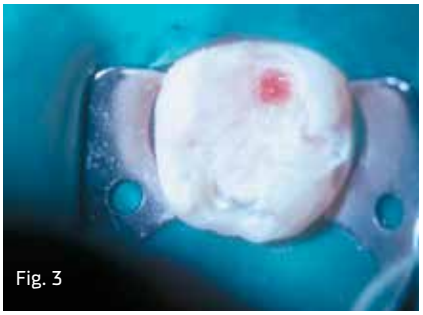

Fig. 3

A treatment for primal incisors

Anecdotal claims that pulpotomies are unsuccessful in primary incisors are unfounded. There was no significant difference in success rates of pulpotomies and pulpectomies in the pulp treatment of asymptomatic vital primary incisors.[11]

Vital calcium hydroxide pulpotomy should not be confused with nonvital techniques that employ fixatives and escharotic agents. Fixatives such as Formocresol are no longer acceptable and raise serious health concerns.[12,13,14,15,16]

Berk provided comprehensive details on differential diagnosis, indications and contraindications, and clinical procedures for vital pulpotomy that proved successful in the treatment of both primary and permanent teeth over a period of 60 years.[1]

The treatment plan is determined by the condition of the odontoblastic membrane and the pulp tissue. The prognosis for vital pulpotomy is good even if the odontoblastic membrane has been pathologically penetrated, provided the disease process is confined within the coronal pulp tissue (Fig. 1). If the odontoblastic membrane has been mechanically penetrated and cannot be clinically evaluated, the health of the radicular pulp can be determined by amputating the coronal pulp tissue at the orifice of the canals. Normal clotting time indicates that the radicular pulp is healthy and the prognosis for vital pulpotomy is favorable.[1]

Favorable conditions for vital pulpotomy include a normal radiographic appearance, absence of sensitivity to percussion, not more than a momentary response to thermal change, not more than a small, beadlike serous or purulent exudate without odor, and not more than a reasonable amount of hemorrhage at the exposure site that clots within normal time limits.[1] If, after amputating the coronal pulp tissue, clotting occurs in the normal amount of time, there is an excellent chance that vital pulpotomy will be successful. If bleeding cannot be controlled, or if there is no bleeding whatsoever, then root canal therapy is indicated.

The roots of pulpotomy and calcium hydroxide

Berk and Zander first conducted pulpotomy studies on dog's teeth using calcium hydroxide in aqueous methylcellulose, calcium hydroxide in water, and zinc oxide-eugenol. Histological evaluation after two months revealed that superior results were obtained with calcium hydroxide in aqueous methylcellulose, which stimulated more rapid healing with the formation of regular tubular dentin (Fig. 2).[1]

Encouraged by the success of the dog studies, Berk performed his first human vital calcium hydroxide pulpotomy on a 12-year-old boy, Norman, in 1946. This young patient had a severe toothache. and opening the tooth revealed a large carious exposure of his mandibular left permanent molar (#19). The roof of the pulp chamber was removed, exposing a healthy, intact odontoblastic membrane. Pulpotomy was performed and a dressing of calcium hydroxide in aqueous methylcellulose (Pulpdent Paste) was placed against the radicular pulp tissue and sealed in place with a hard base of zinc phosphate cement. The tooth was restored with amalgam. This case was done a decade before Berk conducted studies on direct pulp capping at the National Institutes of Health in the mid-1950s.[1]

Procedural steps

When performing vital pulpotomy, the practitioner follows the basic tenets of surgery: case selection, isolation, asepsis, precise surgical technique and wound dressing. To minimize contamination of the pulp, vital pulpotomy should be performed as soon as possible after exposure caused by a fracture or the removal of caries. The following steps will provide the best results for permanent molars with slight modifications for access to anterior teeth, bicuspids and primary molars.[1]

1. Obtain profound anesthesia. Use supplementary periodontal ligament, palatal or lingual injections when necessary, but do not inject directly into the pulp.
2. Isolate the tooth with rubber dam.

3. Prepare the cavity. The primary concern is to avoid contaminating the pulp with saliva or dentin debris. Remove all caries and prepare tooth for restoration before dissecting the roof of the pulp chamber. (Fig. 3)
4. Dissect the roof of the pulp chamber by circumscribing the dentin overlying the pulp with a #4 round bur, which provides maximum control and precision. (Fig. 4)
5. Create a ledge around the periphery of the pulp chamber by cutting slightly into the side walls. (Fig. 5)
6. A disk of dentin will now be resting on the odontoblastic membrane. Cleanse the cavity with sterile saline or sodium hypochlorite to remove all dentin dust and debris. (Fig. 6)
7. Remove the disk of dentin from the roof of the pulp chamber with a spoon excavator. There should be little or no bleeding. (Fig. 7)
8. Inspect the odontoblastic membrane. It should be healthy and intact, and appear as a shiny, glossy sheath with a purplish gray color. It should be firm and resilient, and after slight pressure is applied it should return to its original shape. Otherwise, vital

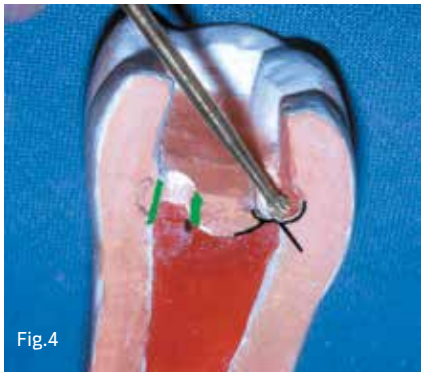
Fig.4


Fig. 5

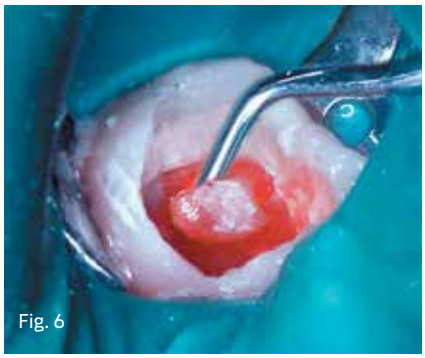
Fig. 6


Fig. 7

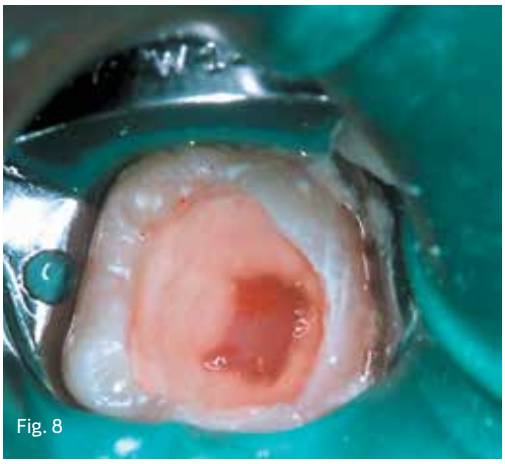
Fig. 8

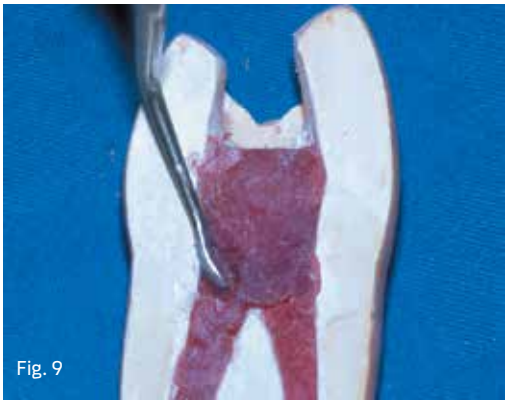
Fig. 9

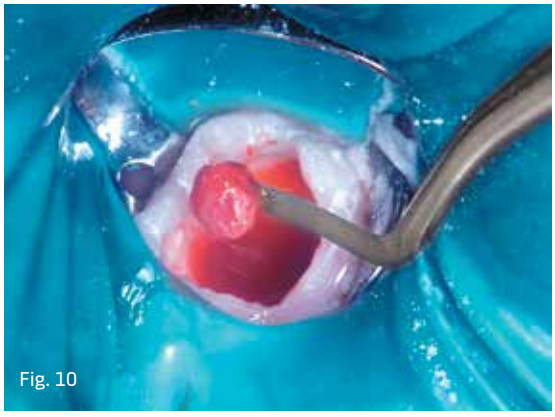
Fig. 10


Fig. 11

pulpotomy is not indicated. (Fig. 8)

9. Amputate the coronal pulp tissue by sliding a sharp spoon excavator down the sidewall of the cavity opposite the initial site of exposure to the level of the orifices of the root canal, then cut horizontally across the orifices and separate the coronal pulp tissue from the radicular pulp. Remove the amputated pulp from the chamber. (Figs. 9 and 10)
10. Control bleeding by packing the pulp chamber with sterile cotton pellets. The cotton can be moistened with local anesthetic containing epinephrine, but never escharotic agents such as phenol.
11. Clotting should occur in a normal period of time; otherwise, the radicular pulp is not healthy and should be removed.
12. Place a 2- to 3-millimeter layer of Pulpdent Paste or Multi-Cal over the amputated stumps as a pulpal dressing (Fig. 11), dry the surface of the paste with a slow flow of air, and gently tamp the paste with a cotton pellet to make sure it's in contact with the pulp. The dry crust prevents the paste from sticking to the cotton and pulling away from the pulp.
13. Using a low-viscosity cement or flowable resin as a hard base, flow the material over the calcium hydroxide paste without exerting any pressure on the pulpal dressing. To do this, allow the material to flow down the side of the cavity preparation and over the paste to the opposing wall so that it fills the cavity to just above the ledge. Light-cure or allow the base to harden. The ledge acts as a physical stop to prevent the base and pulpal dressing from being forced into the stroma of the pulp.
14. If necessary, trim the hard base to receive the restoration (Fig. 12). A final restoration can be placed at the same visit. If a provisional restoration is placed, avoid any possibility of disturbing the healing process by


Fig. 12


Fig. 13

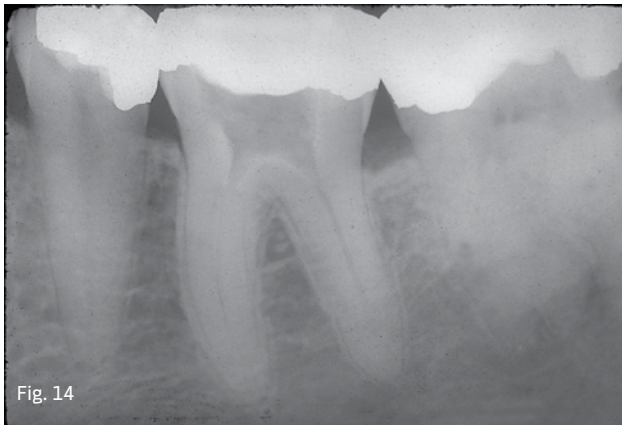
Fig. 14

leaving the provisional restoration and hard base in place for at least three months before placing a final restoration and completing the treatment. Fig. 13 shows a healed pulpotomy with new dentin bridge formation six months after pulpotomy of a mandibular right first molar (#30).

Case study: 1946–2016

A radiograph taken in 1946, three months after Norman's pulpotomy procedure on tooth #19, shows a healthy tooth with dense new dentin bridges (Fig. 14). A radiolucent formula of Pulpdent Paste was used in this early case; in later years, barium sulfate was added to improve the radiopacity.

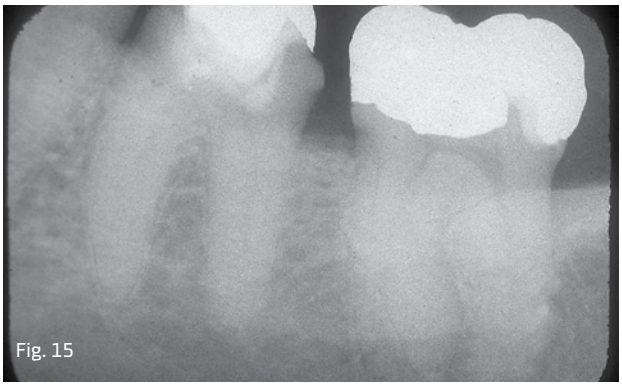
Fig. 15


Fig. 16


Fig. 17


Fig. 18

Thirty-eight years later, Norman, then 50, developed secondary decay on #19, and a crown was made. Fig. 15, pg. shows the crown preparation and a healthy vital tooth in 1984.

Fig. 16 is the golden anniversary radiograph. Taken in 1996, 50 years after pulpotomy, Norman's #19 remains healthy and vital with the crown still in place.

A search of the literature has not revealed any other cases reporting on 50 years' postoperative results. Berk reported that he evaluated Norman on Sept. 12, 2000, and that the tooth was vital with the crown in place.[1]

On Feb. 10, 2016—70 years after the vital calcium hydroxide pulpotomy performed by Berk—Norman was examined by Ali Maddahi, MS, DMD. Fig. 17 is a radiograph of #19 taken at that visit, showing a vital, healthy tooth with an intact PFM crown and healthy periodontium (Fig. 18). To the best of our knowledge, this is the longest case history ever reported in the dental literature.

Conclusion

Vital calcium hydroxide pulpotomy is a simple surgical procedure that provides cost and time savings while maintaining the vitality of teeth. This benefits patients in both the short and long term and, when indicated, is a viable alternative to root canal therapy. Success is determined by the ability of the clinician to evaluate the condition of the odontoblastic membrane and the pulp, assess the prognosis for successful treatment based on the established criteria, and attend to asepsis, the prescribed surgical procedure, and proper dressing and protection of the wound and surgical site. ■

References

1. *Berk H. Save That Tooth. Pulpdent Corporation 2005;127-175.*
2. *Herman BW. Dentinobliteration Der worzel-kanalen nach behandling mit calcium. Zahn Rundschau 1930;39:888-889, Heft 21.*
3. *Teuscher GW, Zander HA. Preliminary report on pulpotomy. Northwestern Univ Bull 1938;39(Dec):4-8.*
4. *Zander HA. Reaction of the pulp to calcium hydroxide. J Dent Res 1939;18:370-373.*
5. *Zander HA, Law DB. Pulp management is fractures of young permanent teeth. JADA 1942;29:737-741.*
6. *Zander HA, Glass RL. Pulp healing. J Dent Res 1949;28:97-107.*
7. *Berk H. The effect of calcium hydroxide methyl cellulose paste on the dental pulp. J Dent Child 1950;17(4):65-68.*
8. *Stanley HR. Pulp capping: conserving the pulp, can it be done? Is it worth it? Oral Surg Oral Med Oral Pathol 1989;68:628-639.*
9. *Mohammadi Z, Dummer PM. Properties and applications of calcium hydroxide in endodontics and dental traumatology. Int Endod J 2011;44(8):697-730.*
10. *Bai J, Qin M, Ji AP. Clinical investigation of pulpotomy with Pulpdent Multi-Cal in young permanent anterior teeth. Journal of Peking University (health Sciences) 2011; Dc. 18; 43(6): 882-5.*
11. *Howley B, et al. Pulpotomy versus pulpectomy for carious vital primary incisors: randomized controlled trial. Pediatr Dent 2012;34(5):112-119.*
12. *Block RM, et al. Cell-mediated immune response to dog pulp tissue altered by Formocresol within the root canal. J Endo 1977; 3(11):424-428.*
13. *Hata G, et al. Systemic distribution of 14C-labeled formaldehyde applied in the root canal following pulpectomy. J Endo 1989;15(11):539-543.*
14. *Lewis B. Formaldehyde in dentistry: a review for the millennium. J Ped Dent 1998;22:167-177.*
15. *Lewis B, Chestner SB. Formaldehyde in dentistry: a review of mutagenic and carcinogenic potential. JADA 1981;103:429-434.*
16. *Myers DR, et al. Distribution of 14C-formaldehyde after pulpotomy with formocresol. JADA 1978;96:805-13.*