

Aesthetic Management

Using Dermal Fillers in a Patient with Deficient Dental Volume

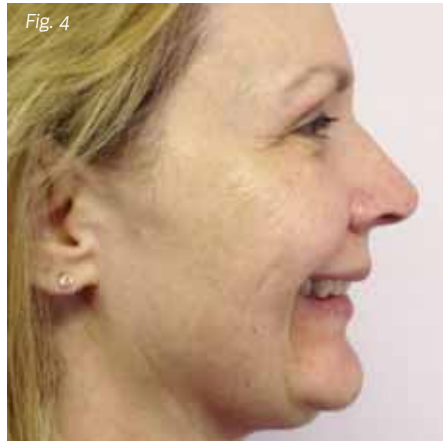
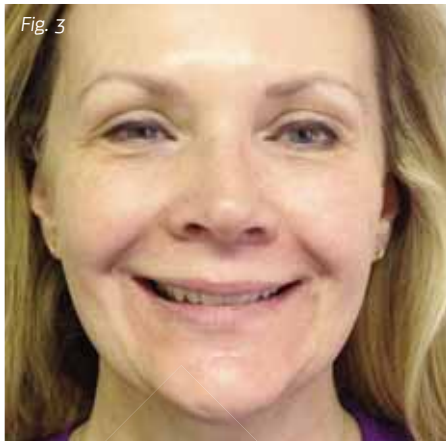
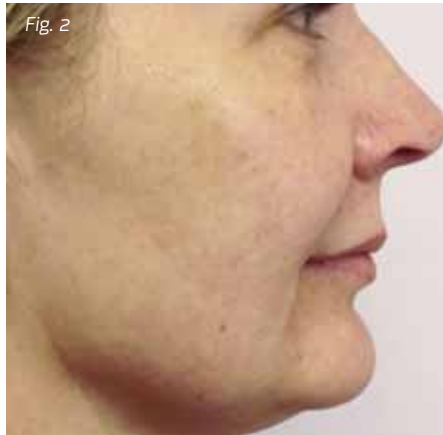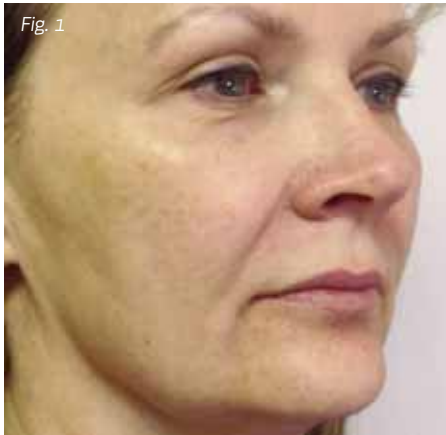by Scott Frey, DDS, and Louis Malcmacher DDS, MAGD

Aesthetic treatments to create a more youthful appearance have become increasingly popular and many adults are specifically seeking cosmetic enhancement of the lips and smile. However, deficiencies in dental volume frequently need to be corrected or camouflaged in order to restore peri-oral contours to a more youthful and dental aesthetic form. This case report is presented as an illustrative example of the challenges of re-establishing facial harmony and masking underlying dental problems to re-establish proper dental aesthetics using dermal fillers.

The following patient presented for dental aesthetic therapy with a chief concern of a “jowly appearance,” and a comprehensive dentofacial assessment was performed. The oblique extra-oral view (Fig. 1) demonstrated the patient’s macro-aesthetic features with pertinent findings being:

1. Descent of the anterior cheek mass and prominent nasolabial folds which hide the upper teeth.
2. A “jowled” appearance with reduced definition of the jawline and mild volume loss in the pre-jowl sulcus lateral to the chin pad.
3. Downturned oral commissures and marionette lines which will prevent showing the dentition when she attempts to smile.
4. Reduced vermilion display of the lips resulting in improper lip and smile lines relative to the dentition.

continued on page 74



Her profile image (Fig. 2) exhibited significantly retruded lips and an excessive mentolabial sulcus. Upon smiling, asymmetric lip elevation was apparent and the quality of her smile appeared notably guarded (Fig. 3). Examination of her profile while smiling (Fig. 4), revealed significant retroclination and retrusion of the dentition of her upper incisors (relative to Andrew's goal anterior limit line).

During the patient interview, it was disclosed that she had been treated orthodontically as a child and that four bicuspid were extracted as part of her orthodontic treatment. While dentoalveolar deficiencies are frequently due to congenital underdevelopment, they can also be produced orthodontically through over-retraction of the dentition, especially in bicuspid extraction cases. Extractions might indeed be necessary in a number of cases to achieve both macro-aesthetic and micro-aesthetic goals in treatment, but the decision must be approached with regard to the facial

changes that occur with age. Orthodontic anchorage also must be carefully managed to avoid facial decline. Although it would be unwise to make assumptions about the nature of this patient's hard tissue insufficiency, it is obvious that deficient hard tissue support from the dentition has contributed to her accelerated soft tissue descent, which is her chief concern.

Ideal dental aesthetic rejuvenative treatment for this patient would include surgically assisted orthodontics and veneers to improve incisor position, color and contour as well as restore dentoalveolar volume by moving tooth mass forward in the face. An increase in dental volume through orthodontics and veneering would also facilitate improved volumization with dermal fillers as the soft tissues become more responsive with adequate hard tissue support. However, the patient declined treatment of the dentition. The patient also elected not to address her asymmetric lip elevation with botulinum toxin (Botox) as this was not a major concern for her.

Restoring Peri-oral Volume

Achieving greater dental and facial harmony using dermal fillers requires comprehensive treatment of the peri-oral region and lips to mimic what would have been achieved with the orthognathic surgery that she declined. Treatment of the patient's pre-jowl sulcus, labiomenal fold, and marionette lines will produce a more defined jawline and bring the depth of the labiomenal crease more in line with the lower lip and chin. Volume added adjacent to the chin and to the marionette lines will help to lift the patient's down-turned oral commissures by increasing structural support. Additionally, volumization of the patient's nasolabial folds will attenuate the droopy appearance of the anterior cheek mass so that the upper lip will have more support and she can have a wider aesthetic smile. The lip augmentation will address the patient's diminished vermilion display and attempt to create fuller lips to establish a proper

continued on page 76

"Injectable pharmacologics such as Botox and dermal fillers have now become mainstream in the dental profession."

smile lip line, where, in a full smile, the bottom of the upper lip will straddle the gingival margins of the upper central incisors. Focusing solely on facial lines and folds would fail to address the underlying dentoalveolar insufficiency and lead to an unbalanced result.

The clinician must be fully aware of the dynamic interplay between different facial regions and how each affects the other. For instance, volumizing the labiomental crease, though important in addressing the soft tissue consequences of deficient dentoalveolar volume, can reduce lower vermilion display. Alternatively, volumization of the nasolabial folds can weigh down the oral commissures from the additional mass added superior to the lips and would negate the positive effects achieved by treatment of the marionette lines. Furthermore, treatment of the peri-oral regions without lip augmentation would negatively impact vermilion display, increase relative lip retrusion and would not accomplish the dental aesthetic goals that need to be achieved.

Treatment

In order to facilitate precise delivery and placement of the dermal fillers, profound anesthesia was attained prior to treatment by performing long buccal, infraorbital and mental dental blocks 2% lidocaine with 1:100,000 epinephrine.

The lower lip-chin complex was treated first. Radiesse 1.5ml (Merz Aesthetics), a resorbable calcium hydroxylapatite material in a gel carrier, was the author's dermal filler of choice for volume restoration in this region. Prior to delivery, the Radiesse was mixed with

continued on page 78



Botox®
and Dermal Filler Training

THE BEST LIVE PATIENT TRAINING AVAILABLE... ANYWHERE

In this exciting course, you will learn how to easily integrate Botox and dermal filler therapy for many esthetic and therapeutic uses in the oral-maxillofacial areas for treatment of TMJ, facial pain, smile design and subtle lip enhancement.

UPCOMING COURSE DATES

- Jan 18-19 Los Angeles (Level I, II)
- Jan 25-26 Chicago (Level I, II)
- Jan 25-26 Houston
- Feb 1-2 Phoenix
- Feb 1-2 Detroit
- Feb 15-16 Columbus, OH (Level I, II)
- Feb 22-23 Fairfax, VA
- Mar 1-2 Louisville
- Mar 1-2 Albuquerque



SCAN FOR DETAILS

Frontline™
and Facial Pain Therapy
for Every Dental Practice

LIVE PATIENT TWO DAY COURSE

With Dr. Louis Malcacher and the AAFE Faculty

This course is the missing link for learning how to comprehensively evaluate, diagnose and treat those suffering from TMJ syndrome and myofascial pain.

UPCOMING COURSE DATES

- Jan 17-18 Los Angeles
- Jan 24-25 Chicago
- Feb 14-15 Columbus, OH
- Mar 7-8 Dallas
- Mar 14-15 New York

REGISTER BEFORE FEB 1ST & SAVE!

- Sign Up Now and Save Up to \$700
- Register for All Three Days and Save \$1100
- Earn Up to 24 CE Participation Hours

REGISTER TODAY! CALL 800.952.0521 :: WWW.FACIALESTHETICS.ORG

0.3ml of 2% lidocaine without epinephrine. Due to the abundance of vasculature crossing the jawline in the area of the pre-jowl sulcus, a flexible cannula 27g x 38mm was used to prevent intravascular injection and to reduce bruising. A small entrance hole was made with a 21g x 1.5 in needle (Terumo Medical) to facilitate entry of the cannula into the deep dermal layer. Approximately 2ml of Radiesse were delivered into the pre-jowl sulcus, labiomental fold and marionette lines. Molding and smoothing of the delivered dermal filler material was performed as needed.

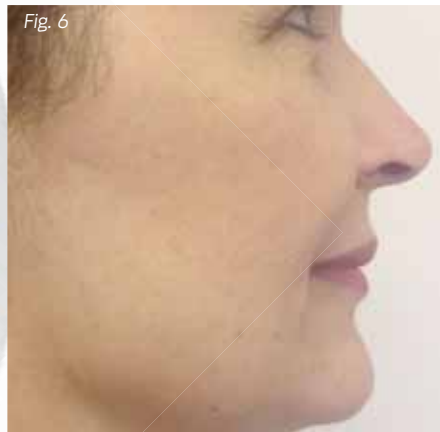Following treatment of the lower lip-chin complex, the nasolabial folds were filled using 1.5ml of Radiesse using the same cannula technique described above. Care was taken not to over-treat the nasolabial folds and counteract the lift to the oral commissures attained by treatment of the marionette lines.

Subsequent to treatment of the perioral regions, lip augmentation was performed. Juvederm XC 1.0ml (Allergan), a resorbable cross-linked hyaluronic acid with lidocaine, was utilized for ideal lip volumization. A total of 0.8ml Juvederm XC was delivered into the bodies of the upper and lower lips until an appropriate relationship to the surrounding soft tissues was achieved. Particular attention was paid to the labiomental crease. The delivered material was sculpted to provide appropriate contours and the remaining 0.2ml of Juvederm XC was used to fill superficial rhytids.

The final result was assessed three weeks post-operatively (Fig. 5, 6). The patient's dental aesthetic and facial balance was enhanced remarkably. There was notable improvement in the jawline, labiomental crease, oral commissures, vermilion display, lip lines, smile design and lip contour. Additionally, she smiles with much more confidence in spite of unaddressed dental issues (Fig. 7).

Final Remarks

Injectable pharmacologics such as Botox and dermal fillers have now become mainstream in the dental profession. This clinical case demonstrates the profound role dermal fillers in the oral and maxillofacial areas can play in addressing dental aesthetic problems integral to treatment of the smile and peri-oral region. The relationships between a patient's dentition, the surrounding soft tissue and the patient's facial characteristics are both intimate and dynamic and cannot be ignored. I would highly recommend that all dental professionals become interested in providing these dental aesthetic treatments themselves as all dentists have the skill set to learn how to successfully place Botox and dermal fillers. Having had extensive training with the American Academy of Facial Esthetics, I personally have become very comfortable with the utilization of injectable pharmacologics in practice as primary therapy for dental aesthetic and dental therapeutic uses and find them extremely important in expanding the treatment of aesthetic dental options.



As health-care professionals delivering therapeutic treatment in the oral and maxillofacial areas, it is our moral, ethical and legal responsibility to give the patient all of the available options for treatment. The American Academy of Facial Esthetics teaches over 80 live patient training programs annually for dentistry including at dental university continuing education programs and major dental meetings. It is time for every dental professional to learn to provide these services so they can provide non-invasive and non-surgical excellent aesthetic and therapeutic outcomes for their patients.

* Dentistry performed by Dr. Scott Frey ■

Author Bios



Dr. Scott Frey graduated with honors from the University of the Pacific Arthur A Dugoni School of Dentistry. Following graduation, Dr. Frey held a part-time faculty position at the University of the Pacific teaching dental occlusion and aesthetics while working in private practice. For achievements in preventive and minimally invasive dentistry, he was inducted as a Fellow to the World Congress of Minimally Invasive Dentistry and has gone on to found MorethanSmiles.org. Dr. Frey is an accredited member and mentor for the American Academy of Facial Esthetics and is currently completing his residency in Orthodontics at the University of Colorado.



Dr. Louis Malcmacher is a practicing general dentist and an internationally known lecturer, author and dental consultant known for his comprehensive and entertaining style. Dr. Malcmacher is president of the American Academy of Facial Esthetics (www.FacialEsthetics.org). You can contact him at 800-952-0521 or e-mail drlouis@FacialEsthetics.com. His website is www.commonssensedentistry.com where you can find information about his hottest topics, hands-on lecture schedule and live patient Botox and dermal fillers training, and sign up for a free monthly e-newsletter.



PARADISE DENTAL TECHNOLOGIES

Creators of the Montana Jack® and Innovators of Dental Product Design



Feel the difference when working with PDT instruments: they are lighter, more tactile sensitive, and even patients can feel the difference. Our designs are precisely fine tuned, providing access and adaptability like no others. The durability of our advanced formula steel is unsurpassed, outlasting more expensive instruments multiple times.



Montana Jack®

The original & still unmatched!

Superior Quality. Lower Price. Best Value!

100% Satisfaction Guarantee!



Join our social media network for weekly updates, and additional deals!

www.pdtdental.com